



THERMAL BREAST IMAGING REPORT

Patient: Sample Patient
 Technician: Annette Adams, CTT
 Imaging Center: Midwest Thermography

DoB: 11/11/1966

Date of Scan: 05/25/2018
 Date of Report: 05/30/2018

Dear Ms. Patient,

Thank you for the opportunity to review your images. The results are detailed below. To properly understand these results, we strongly recommend that you read Procedure and Limitations description section and the "Understanding Your Thermal Imaging Scan" guide at the end of this report.

Relevant History: You have no current breast concerns. Physical breast examination of 2016 was normal. There was no history of breast radiology. You have a family history of breast cancer. Thermal imaging of May 1, 2014 was rated right TH 2, left TH 2 by Dr. Tolmosoff.

Results and Conclusions: Developing right breast findings suggest medium to high risk. Thermography findings provide information related to superficial inflammation and circulation as a possible risk factor for breast disease. It cannot diagnose or rule out the possibility of breast disease or cancer and should not delay additional evaluation, screening, or monitoring of either breast or any concerns that may be present including those mentioned in your history.

Thermal (TH) Risk Rating for Each Breast: This unique TH rating describes the level of inflammation and blood vessel activity in your breasts which can contribute to both current and future risk. The higher the rating, the greater the risk.

Your Risk Ratings:	Right: TH 3+	Left: TH 2							
<table style="width: 100%; border-collapse: collapse;"> <tr> <td style="width: 16.6%;">LOW</td> <td style="width: 16.6%;">TH-1</td> <td style="width: 16.6%;">TH-2</td> <td style="width: 16.6%;">TH-3</td> <td style="width: 16.6%;">TH-4</td> <td style="width: 16.6%;">TH-5</td> <td style="width: 16.6%;">HIGH</td> </tr> </table>			LOW	TH-1	TH-2	TH-3	TH-4	TH-5	HIGH
LOW	TH-1	TH-2	TH-3	TH-4	TH-5	HIGH			
<p><i>A (+) or (-) after the TH value indicates a rating between TH grades.</i></p>									

Hormonal Grade for Estrogen Activity: This grade describes the level of estrogen activity occurring in your breasts. This activity can be associated with breast pain, breast lumps and/or increased risk.

Your Hormonal Grade for Estrogen Activity:	3							
<table style="width: 100%; border-collapse: collapse;"> <tr> <td style="width: 16.6%;">NONE</td> <td style="width: 16.6%;">0</td> <td style="width: 16.6%;">1</td> <td style="width: 16.6%;">2</td> <td style="width: 16.6%;">3</td> <td style="width: 16.6%;">4</td> <td style="width: 16.6%;">HIGH</td> </tr> </table>		NONE	0	1	2	3	4	HIGH
NONE	0	1	2	3	4	HIGH		
<p><i>Note: Mild whole breast inflammation and congested lymph can simulate the appearance of estrogen activity.</i></p>								

Follow-Up Recommendations: I recommend that you see your doctor for further evaluation of the thermal findings in your right breast to determine potential sources of inflammation, vascular activity and risk. Please also follow up with your doctor specifically with regards to all breast and axillary symptoms, concerns, and exam findings that are currently present include those listed in your history. All concerns including but not limited to lumps, skin changes, clinical findings and radiographic findings require medical evaluation regardless of the thermal imaging results. I recommend that you return for follow-up thermal breast imaging in three to six months to determine if there are any changes to your level of risk. Since thermal imaging is designed to be used in combination with other examinations rather than a stand-alone detection technology, please follow your doctor's recommendations regarding additional breast examinations.

Findings Contributing to Your Results: The notable temperature patterns listed below represent areas of inflammation and vascular activity contributing to your risk rating along with findings to be monitored on future examinations. When temperature differences between breasts exceed the normal range, a finding is considered to be more significant than one within normal limits.

Notable Temperature Patterns:

- Stable symmetrical vascular warming extending to the nipple line consistent with high estrogen activity.
- Greater right inner breast vascular warming outside the normal range.
- Greater right areola warming outside the normal range.
- Greater right lower inner quadrant vascular warming outside the normal range.
- No significant response to the cold challenge in either breast. Since this lack of response was symmetrical, it does not affect the risk rating.

Findings Dependent on Temperature Differences Between Breasts:

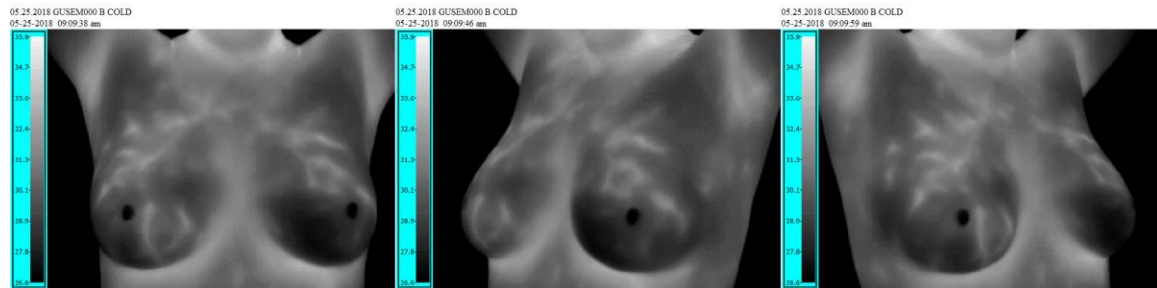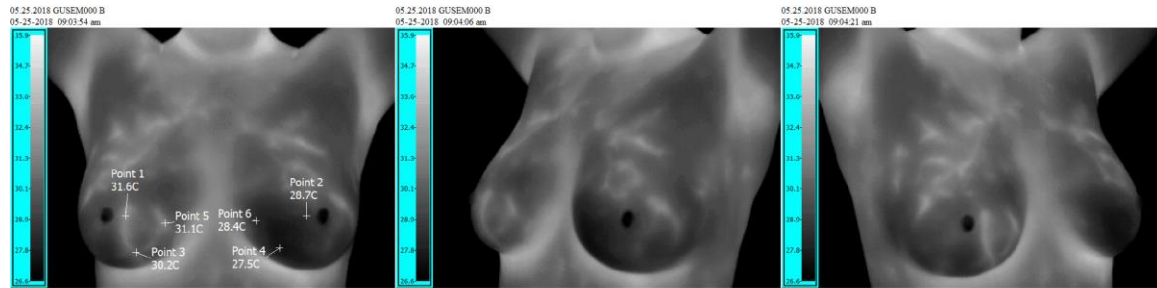Finding	Temp Difference	Normal Range
Right Inner Breast Vascular Warming	2.70 Deg C	0.00 - 2.00 Deg C
Right Areola at 3 o'clock	2.90 Deg C	0.00 - 1.50 Deg C
Right Lower Inner Quadrant Vascular Warming	2.70 Deg C	0.00 - 1.00 Deg C

Procedure Description and Limitations: Thermal breast imaging (breast thermography) is a breast health risk assessment tool that is used in addition to standard breast screening and/or diagnostic examinations. It is not a stand-alone examination and cannot diagnose or rule out the presence of breast cancer regardless of the risk rating assigned. When interpreting these images, we look for unusual patterns of blood vessels and warming that can suggest inflammation or unusual vascular activity. Inflammation and unusual vascular activity may suggest risk for the presence of breast cancer or risk for developing cancer in the future. Since the causes of the thermography findings cannot be determined by the images alone, additional examinations are always required before a final diagnosis can be made. This examination was performed using a high-resolution computerized thermal imaging camera in a controlled environment after following strict pre-examination protocols to insure the accuracy of the findings.

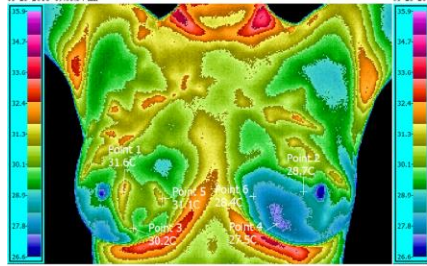


Robert L. Kane, DC, DABCT, FIACT
Board Certified Clinical Thermologist

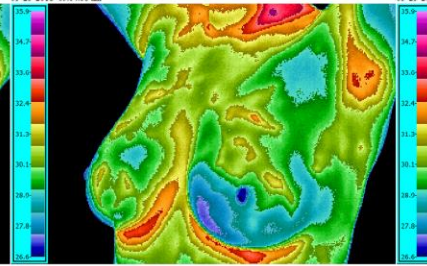
Diplomate American Board of Clinical Thermography
Diplomate International Academy of Clinical Thermology
Fellow International Academy of Clinical Thermology



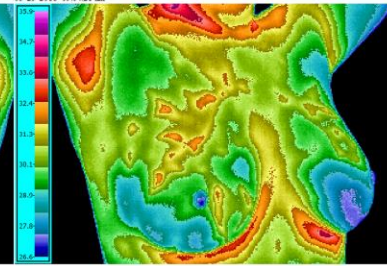
05-25-2018 GUSEM000 B
05-25-2018 09:03:54 am



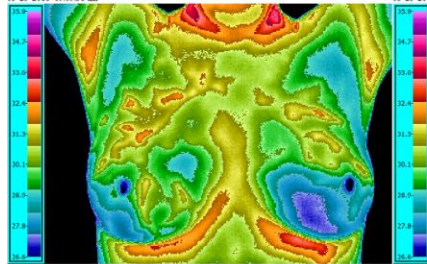
05-25-2018 GUSEM000 B
05-25-2018 09:04:06 am



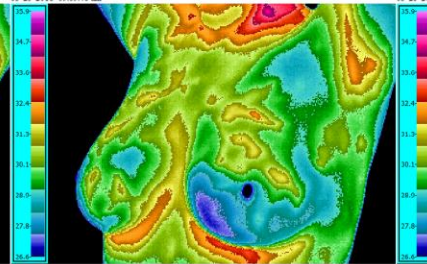
05-25-2018 GUSEM000 B
05-25-2018 09:04:21 am



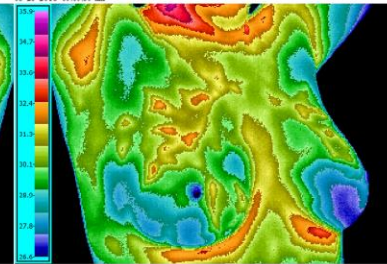
05-25-2018 GUSEM000 B COLD
05-25-2018 09:09:38 am



05-25-2018 GUSEM000 B COLD
05-25-2018 09:09:46 am



05-25-2018 GUSEM000 B COLD
05-25-2018 09:09:59 am



Understanding Your Thermal Breast Imaging Scan

Introduction:

Thermal breast imaging (Thermography) is a tool that measures heat from the surface of the body and allows us to visualize areas of inflammation and vascular activity that may signal increased risk for breast cancer. It does not directly detect or diagnose cancer but can help reach those goals. It is designed to be used as a complement to other breast examinations and not a replacement for mammography or any other diagnostic or screening examination.

Unlike screening examinations or diagnostic examinations, the findings can suggest risk for currently having breast cancer or for developing it in the future. This information can be used to help determine when additional testing or intervention designed to lower risk is necessary. By watching for changes from examination to examination, Thermal Imaging can also help monitor the effects of interventions to see if they are effective. Interventions include things such as modifying one's diet or lifestyle, improving nutrition or supervised care by a health care provider among others.

How Are The Images Analyzed?

The analysis is based upon deviations from the normal symmetry of the breast temperature.

Temperature Patterns and Temperature Differences Between Breasts - The temperature is analyzed by looking at the patterns of warming and cooling (called notable temperature patterns) as well as the side to side differences between breasts. The actual breast temperature is seldom a factor. Once identified, temperature patterns and temperature differences are evaluated to determine if they are significant enough to contribute to your risk rating based on the Thermobiological (TH) rating scale as taught by William Hobbins, MD. Findings that are considered significant along with findings that are being watched for change are recorded in your report.

Mastectomy- In the case of mastectomy, the ability to compare from side to side is lost. This is true even when reconstruction has been performed. The remaining breast and mastectomy region are analyzed based upon temperature patterns only and the mastectomy region is rated simply as low/medium/high risk rather than the standard TH scale.

Radiation - When radiation therapy for cancer is performed to the breast, it frequently warms the breast for a period of years subsequent to completing the course of treatment. Consequently, the untreated breast may be analyzed based on temperature pattern only. The irradiated breast is evaluated normally with the understanding that the radiation warming may be simulating signs of inflammation. The breast is then monitored for stability and eventual resolution as the effects of the radiation diminish.

TH 1 and 2: Low Risk – Low Inflammation/Vascular Activity

Based upon temperature analysis only, this rating suggests a low risk that breast cancer may be currently present or that it may develop in the future. Since thermal imaging has been cleared as an adjunctive procedure only, this rating cannot guarantee that the breasts are cancer free and should not delay any other breast examination recommended by your doctor. It should not delay evaluation of any lump, skin change, clinical finding, and radiographic finding that may currently be present. When cancer is present, it tends to be growing less quickly (less active) or has not produced enough inflammation or changes to the blood supply so that it is visible on thermal imaging.

The difference in risk between TH1 and TH2 is minimal.

Follow Up Recommendations for TH 1 and TH 2:

Follow-up thermal imaging for women over 30 years of age should be performed annually and, for women 20 to 30 years of age, every 3 years. Thermal imaging should be performed in addition to whatever testing and/or examinations are recommended by your doctor for screening or follow-up of an existing concern.

TH 3: Medium Risk – Medium Inflammation/Vascular Activity

Based upon temperature analysis only, this rating suggests a medium risk that breast cancer may be currently present or that it may develop in the future. Follow-up thermal imaging and other breast examinations such as mammography, breast ultrasound, and breast MRI can help clarify any significance to this rating. When cancer is present it may be more active and growing slightly faster than those found in the lower TH risk categories. This rating can also be caused by conditions such as normal variation in anatomy, some benign tumors, lymphatic activity or congestion and low grade inflammation or infection. It is important to determine the cause of the thermal findings and not prematurely conclude that cancer is present.

Follow Up Recommendations for TH 3:

3-6 month follow-up thermal imaging is recommended depending on your individual situation. Additional imaging such as mammogram or ultrasound should be performed if it has not taken place within the last year. Your doctor will recommend the best test for you. If something is being watched on another examination such as a mammogram, you should consult with your doctor to determine if any additional testing is necessary at this time. Interventions intended to reduce risk can be considered as a preventative measure.

TH 4 and 5: High Risk – High Inflammation/Vascular Activity

This rating suggests a high risk that breast cancer is currently present or that it may develop in the future. Since this rating can also be caused by inflammation, infection and some fast growing benign tumors, it is important to determine the cause of the thermal findings and not prematurely conclude that cancer is present. Other factors such as lymphatic congestion and/or hormone imbalance can contribute to these findings and need to be considered when evaluating their significance. Most women with TH4 ratings do not have cancer at the time of the thermal imaging examination but do indicate high risk for developing cancer in the future.

Follow up Recommendations for TH 4 and TH 5

It is strongly recommended that you consult with your physician and begin additional imaging such as mammography, ultrasound, or any other appropriate test promptly to help clarify the thermal findings. A biopsy may be recommended if this rating occurs in a breast with a lump or other suspicious finding on another examination. Interventions intended to reduce risk are strongly recommended as a preventative measure.

Follow-up thermal imaging should be performed at 3 month intervals or at the discretion of the Thermologist based upon the thermal findings and any intervention being performed.

Modifiers

A plus or minus sign is used to upgrade or downgrade the severity within a particular TH rating.

Hormonal Grade for Estrogen Activity

Visualizing the effects of estrogen on the breast blood supply - Lifetime exposure to estrogen has been identified as a significant risk factor for the development of cancer. While thermal imaging cannot directly measure estrogen, the Hormonal Grade is a way to look at the effects of estrogen on the circulation of the breasts. When we measure the level of estrogen and progesterone in the blood, urine or saliva we are looking at the hormonal balance in the whole body. The question remains, what is the effect of these hormone levels on the breasts. Normal fatty tissue in the breasts can actually produce estrogen and will be missed on blood testing and can contribute to risk. Some women have estrogen receptors that are more sensitive or bind estrogen more easily. They may even have low estrogen levels but their breasts are actually being over stimulated by the estrogen they have. By looking at the hormonal grade, we can help put all of these factors into perspective.

It is important to recognize some additional factors that can affect the hormonal grade that may or may not be the result of estrogen stimulation. Symmetrical low-grade whole breast inflammation from poor lymph flow can produce mottled thermal patterns that can simulate the appearance of estrogen stimulation in the breasts. Altered thyroid function can create mottling and can directly alter the estrogen progesterone balance. In addition, chronic: pain, stress, hormonal imbalance, allergy, illness, (low-grade) infection, exposure to foods/chemicals for which one is sensitive can also affect nervous and/or immune/lymphatic system function creating mottling. When the hormonal grade is at a 3 or 4, all of these factors should be considered.

How are the images analyzed?

This analysis is performed by comparing only the symmetrical patterns that occur in both breasts to those we would expect on women who are pregnant or lactating. The closer the symmetrical patterns appear to the pregnant/lactating woman, the higher the implied estrogen activity in the breasts.

Grade 0– There are no symmetrical blood vessel patterns visualized in the breasts which means the breasts do not appear to be stimulated by estrogen at all. Your breasts appear to be handling the estrogen in your body very well and there is really nothing to be done to restore hormonal balance in the breasts. If you are taking hormone replacement, this rating is great news since it suggests that the estrogen is probably not contributing to any risk you may have for developing cancer. This rating is most common in post menopausal women and is considered to be the healthiest.

Grade 1 – Symmetrical blood vessel patterns are visualized in the chest wall and upper most breast surface only. This suggests a small amount estrogen activity but like Grade 0, suggests that the estrogen in your body is less like to contribute to any risk you may have for developing cancer. This rating is also common in post menopausal women and is considered to be healthy.

Follow-up Recommendations for Hormonal Grade of 0 or 1:

No follow up or management is necessary.

Grade 2 – Symmetrical blood vessel patterns now visualized extending to the upper-inner and/or upper outer quadrants of the breasts. This suggests a slightly higher activity than Grade 1 suggests and the estrogen in your body is less likely contributing to any risk you might have for developing cancer or that the contribution is small. This grade is commonly seen in premenopausal women and is considered to be healthy.

How should you follow up for a Hormonal Grade 2:

Kane Thermal Imaging Services • PO Box 2332 • Redwood City CA 94064 • 650-868-0353

This grade does not necessarily require any follow up or management and may be normal especially for pre-menopausal women. For post menopausal women who are not on hormones, they may wish to work with a holistic practitioner to try to lower the estrogen stimulation to the breasts especially if their TH rating is suggesting any elevation in risk.

Grade 3 – The blood vessel patterns are visualized extending to the level of the nipple line as they do during pregnancy under the effects of estrogen. This suggests moderate estrogen activity and may suggest that estrogen stimulation of the breasts may be contributing to risk for developing cancer in women with TH3 ratings or higher.

Women who are pregnant and lactating will generally have a Hormonal Grade of 3 or 4 due to natural hormonal changes. Also, women on birth control pills and hormone replacement will also commonly exhibit this Hormonal Grade as a function of the hormones they are taking. This grade simply says the level of stimulation is elevated. The TH rating will let you know the level of risk for developing cancer. Other possible causes for this rating included large breast size, poor estrogen-progesterone balance and poor estrogen metabolism.

Grade 4 – The symmetrical blood vessel patterns now are visualized extending below the nipple line. The significance is the same as Grade 3. The level of stimulation is just greater.

Follow-up Recommendations for Hormonal Grade 3 or 4:

If you are pregnant or lactating there is nothing to do. This is completely normal for you and should not generate any concern. If you are taking hormones or birth control pills, this is likely the cause and reducing the activity may not be possible as long as you continue on these medications.

Use the TH rating to determine if there is an elevated level of risk for the breasts. If there is a TH rating of 3 or higher, addressing the estrogen may be a way to lower your risk. If discontinuing treatment is not an option or not desired, watch the TH ratings to see if any increase in risk can be detected and use that with your health care provider to determine if changes to your hormone intake are warranted.

If there are no obvious sources of estrogen that could explain the grade it is time to look at environmental and dietary estrogen, estrogen-progesterone balance and estrogen metabolism along with the additional factors mentioned above. Tips on how to do this may be available from the center where you were imaged or a consultation with a holistic health care provider can be considered.