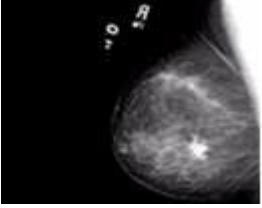
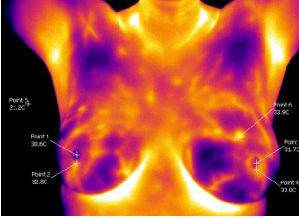
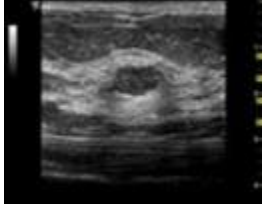


The following table outlines the differences between mammography, thermography and ultrasound.

<p>Mammography</p> 	<p>Thermography</p> 	<p>Ultrasound</p> 
<p>Uses X-rays to produce an image that is a shadow of dense structures. Suspicious areas need to be dense enough to be seen.</p>	<p>Uses infrared sensors to detect heat and increased vascularity (angiogenesis) as the byproduct of biochemical reactions. The heat is compiled into an image for computerized analysis.</p>	<p>High frequency sound waves are bounced off the breast tissue and collected as an echo to produce an image.</p>
<p>Structural imaging. Ability to locate the area of suspicious tissue.</p>	<p>Functional imaging. Detects physiologic changes. Cannot locate the exact area of suspicion inside the breast.</p>	<p>Structural imaging. Ability to locate the area of suspicious tissue.</p>
<p>Early detection method.</p>	<p>Early indication of increased risk. Used as an adjunctive imaging test.</p>	<p>Low spatial resolution (cannot see fine detail). Good at distinguishing solid masses from fluid filled cysts. Used as an adjunctive imaging test.</p>
<p>Findings increase suspicion. Cannot diagnose cancer.</p>	<p>Findings increase suspicion. Cannot diagnose cancer.</p>	<p>Findings increase suspicion. Cannot diagnose cancer.</p>
<p>A biopsy is the only test that can determine if a suspected tissue area is cancerous.</p>		
<p>Can detect tumors in the pre- invasive stage.</p>	<p>May provide the first signal that a problem is developing.</p>	<p>Ability to detect some concerns missed by mammography.</p>
<p>No comparison.</p>	<p>A positive infrared image represents the highest known risk factor for the existence of or future development of breast cancer – 10 times more significant than any family history of the disease.</p>	<p>No comparison.</p>
<p>Hormone use decreases sensitivity.</p>	<p>No known effect.</p>	<p>No known effect.</p>
<p>Large, dense, and fibrocystic breasts increase reading difficulties.</p>	<p>No effect.</p>	<p>No known effect.</p>
<p>Unable to image the underarm region, upper outer quadrants of the breast tissue and next to the chest wall.</p>	<p>Able to image up into the underarm region, outer quadrants of the breast tissue and next to the chest wall.</p>	<p>All areas of the underarm, upper outer quadrants of breast tissue and chest wall can be visualized.</p>

Sources: Index Medicus – ACS, NEJM, JNCI, J Breast, J Radiology, J Clin Ultrasound, Index Medicus – Cancer, AJOG, Thermology, Text – Atlas of Mammography: New Early Signs in Breast Cancer, Text – Biomedical Thermology